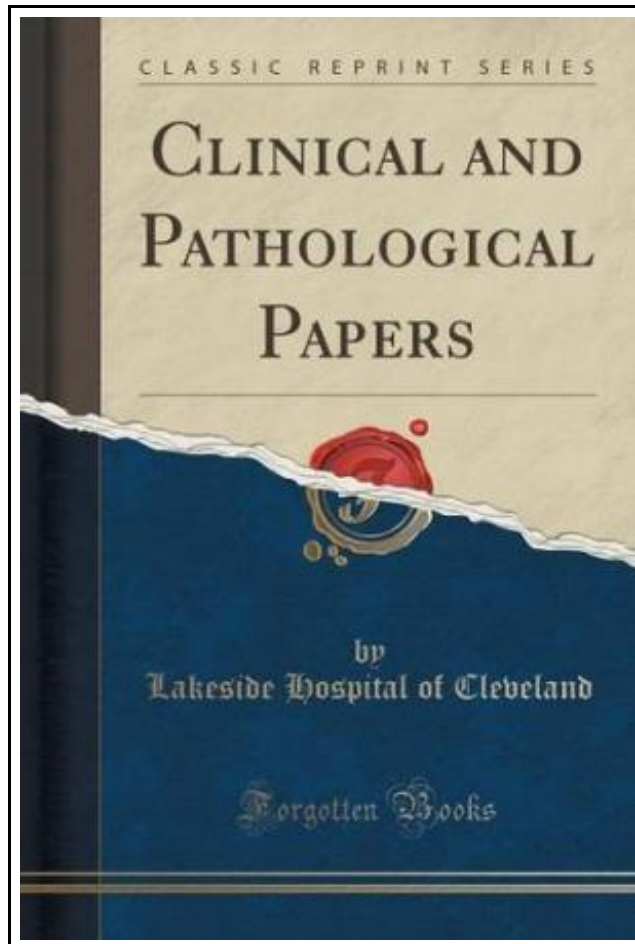


Clinical and Pathological Papers (Classic Reprint) (Paperback)



Filesize: 7.46 MB

Reviews

This ebook will be worth buying. It usually fails to charge too much. You will not sense monotony at at any time of your time (that's what catalogs are for regarding when you check with me).

(Retha Frami V)

CLINICAL AND PATHOLOGICAL PAPERS (CLASSIC REPRINT) (PAPERBACK)

DOWNLOAD



Forgotten Books, United States, 2015. Paperback. Book Condition: New. 229 x 152 mm. Language: English Brand New Book ***** Print on Demand *****.Excerpt from Clinical and Pathological Papers The usual cutaneous manifestation seen in typhoid fever is the presence of rose spots in the form of a maculo-papular eruption appearing on the abdomen. The lesions are pale red at first, later become darker, and appear about the end of the first week, coming out in successive crops. They are usually few in number, but in some patients form a profuse eruption, covering the entire body and extremities, and are occasionally seen on the face. Sometimes the lesions are capped by tiny vesicles, at other times they are hemorrhagic. The other cutaneous lesions seen in typhoid form a very interesting group. Among these may be mentioned herpes, urticaria, sudamina, desquamation, erythema, erysipelas, purpura, furunculosis, abscess, carbuncle, impetigo, onychia, infected sebaceous cyst, decubitus, tache bleuaire, and lines atrophicae. The following description of these conditions is based on a review of the literature, and on a study of their occurrence in 1230 cases of typhoid fever, occurring in the medical services of Drs. Powell, Lowman, Upson, Cushing, and Hoover, at Lakeside Hospital; to these gentlemen I am indebted for the privilege of making this report. Herpes were observed in 12 cases. In 8 cases they appeared on the lips during the first week of the disease. In the other 4 cases the herpetic eruption appeared late in the course of typhoid and in various regions of the body. In 1 case, a female, aged thirty-two years, a number of vesicles appeared on the forty-fourth day of her illness, a short distance outside the external canthus of her left eye and also directly above this near the hair line. Another patient, a boy, aged...



[Read Clinical and Pathological Papers \(Classic Reprint\) \(Paperback\) Online](#)



[Download PDF Clinical and Pathological Papers \(Classic Reprint\) \(Paperback\)](#)

Relevant Books



The Sunday Kindergarten Game Gift and Story: A Manual for Use in the Sunday, Schools and in the Home (Classic Reprint) (Paperback)

Forgotten Books, United States, 2015. Paperback. Book Condition: New. 229 x 152 mm. Language: English . Brand New Book ***** Print on Demand *****.Excerpt from The Sunday Kindergarten Game Gift and Story: A Manual for...

[Read eBook »](#)



The Voyagers Series - Europe: A New Multi-Media Adventure Book 1 (Paperback)

Strength Through Communications, United States, 2011. Paperback. Book Condition: New. 229 x 152 mm. Language: English . Brand New Book ***** Print on Demand *****.The Voyagers Series is a new multi-media, multi-disciplinary approach to teaching...

[Read eBook »](#)



The Voyagers Series - Africa: Book 2 (Paperback)

Voyagers Series, Inc., United States, 2011. Paperback. Book Condition: New. 229 x 152 mm. Language: English . Brand New Book ***** Print on Demand *****.The Voyagers Series is a new multi-media, multi-disciplinary approach to teaching...

[Read eBook »](#)



No Friends?: How to Make Friends Fast and Keep Them (Paperback)

Createspace, United States, 2014. Paperback. Book Condition: New. 229 x 152 mm. Language: English . Brand New Book ***** Print on Demand *****.Do You Have NO Friends? Are you tired of not having any...

[Read eBook »](#)



Plentyofpickles.com (Paperback)

Createspace, United States, 2013. Paperback. Book Condition: New. 229 x 152 mm. Language: English . Brand New Book ***** Print on Demand *****.Interested in taking a peek into the world of internet dating? Then order...

[Read eBook »](#)